

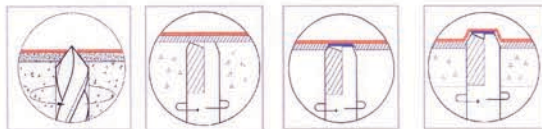
# Evaluation of a New Surgical Technique for Sinus Lift Procedures.



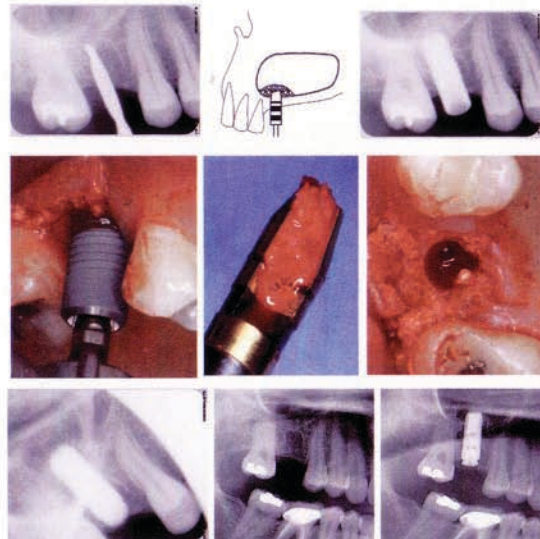
Poster # 39

Jin Kim, DDS - Lecturer, UCLA School of Dentistry; Private Practice, Diamond Bar, CA  
Thomas K. Lee, DDS - Assistant Clinical Professor, UCLA School of Dentistry  
Ik-Jae Kang, DDS - Private Practice, Seoul, Korea

**Background:** Maxillary posterior region have often presented challenges for successful dental implant therapies due to poor bone quality and large sinus cavity resulting in reduced vertical bone volume. Variations of sinus lift procedure techniques utilizing osteotome and lateral window openings have been developed by many clinicians to overcome such challenges. However, literature reports that many complications such as perforation of Schneiderian membrane, obstruction of antero-nasal foramen, oro-nasal fistula formation, infection of the sinus and grafted material, loss of grafted material, severe haemorrhaging, damage to adjacent dentition, and poor wound healing, etc., can arise from sinus lift procedures. Such complications point to inherent difficulties in performing sinus lift procedures, often even for the most experienced clinicians.

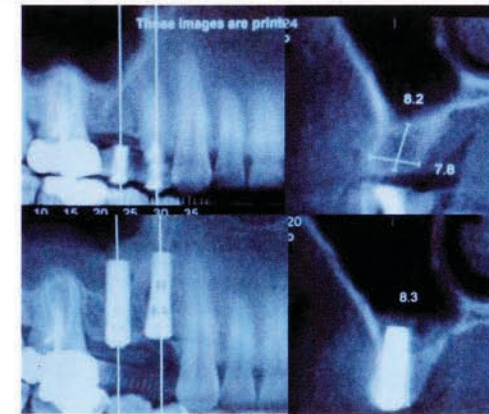


**Materials and Methods:** This prospective study involved 87 implants placed between January 2006 and December 2007. There were 65 patients between the age of 19 to 75, and all 87 implants were placed simultaneously while sinus lift procedure was performed in the affected region utilizing a new surgical technique called Hatch Reamer System.



**Results:** No sinus membrane perforation was observed during the procedure and during post operative follow-up periods. Both clinical and radiographic evaluations were made for each patient. Early results show 2 implant failures due to mobility of implants, resulting in 97.7% success rate so far for the implants placed utilizing this new sinus lift method.

**Conclusion:** This new surgical technique for sinus lift procedure utilizing Hatch Reamer System can be considered relatively safe and predictable in cases where there is insufficient bone height in posterior maxilla.

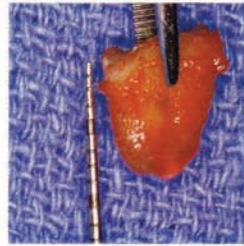
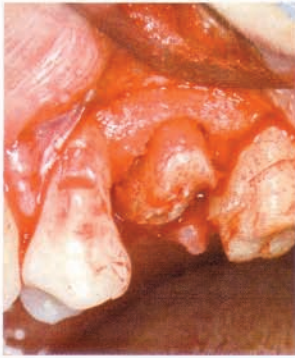


## References:

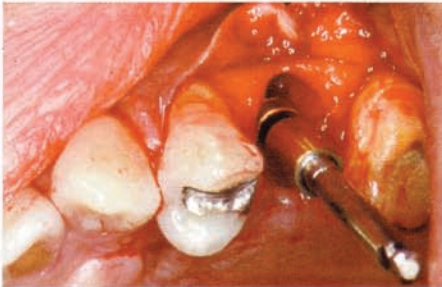
- Aghaloo, T. L. and P. K. Moy (2007). "Which hard tissue augmentation techniques are the most successful in furnishing bony support for implant placement?" *Int J Oral Maxillofac Implants* 22 Suppl: 49-70.
- Del Fabbro, M., T. Testori, et al. (2004). "Systematic review of survival rates for implants placed in the grafted maxillary sinus." *Int J Periodontics Restorative Dent* 24(6): 565-77.
- Fugazzotto, P. A. and J. Vlassis (1998). "Long-term success of sinus augmentation using various surgical approaches and grafting materials." *Int J Oral Maxillofac Implants* 13(1): 52-8.
- Raghoobar, G. M., N. M. Timmenga, et al. (2001). "Maxillary bone grafting for insertion of endosseous implants: results after 12-124 months." *Clin Oral Implants Res* 12(3): 279-86.
- Summers, R. B. (1994). "The osteotome technique: Part 3--Less invasive methods of elevating the sinus floor." *Compendium* 15(6): 698, 700, 702-4 passim; quiz 710.
- Valentini, P., D. Abensur, et al. (2000). "Sinus grafting with porous bone mineral (Bio-Oss) for implant placement: a 5-year study on 15 patients." *Int J Periodontics Restorative Dent* 20(3): 245-53.
- Wallace, S. S. and S. J. Froum (2003). "Effect of maxillary sinus augmentation on the survival of endosseous dental implants. A systematic review." *Ann Periodontol* 8(1): 328-43.

# M.I.S.E. (Minimally Invasive Sinus Elevation™) Technique

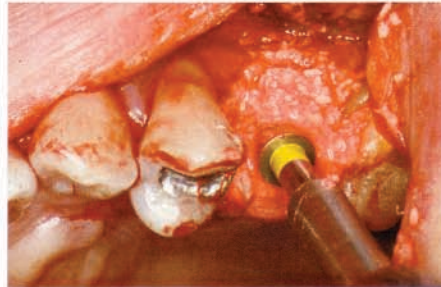
utilizing the **Hatch Reamer™ System**



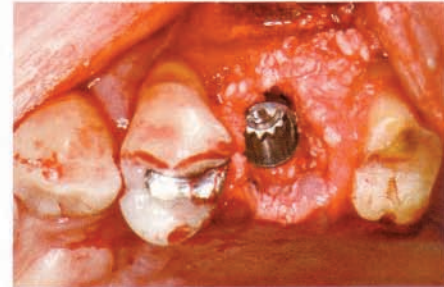
A healthy 46-year old female lost an upper bicuspid. The tooth root measured approximately 8mm. The sinus floor was less than 2mm away from the root apex. A 13mm dental implant was planned.



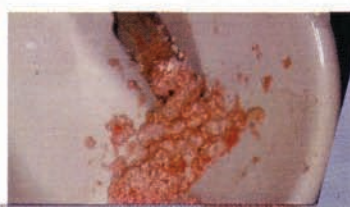
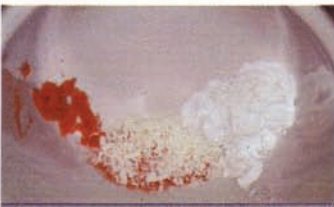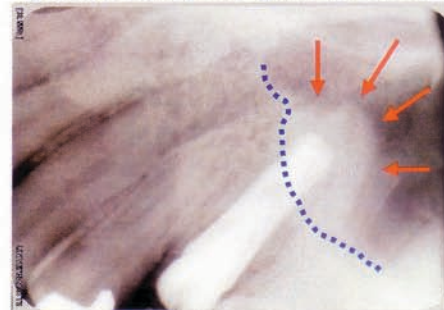
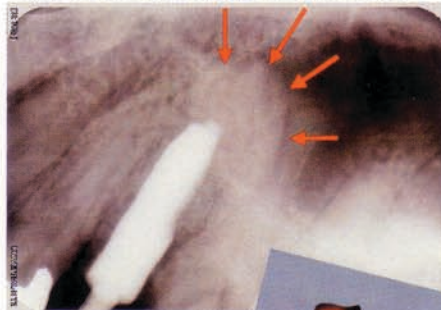
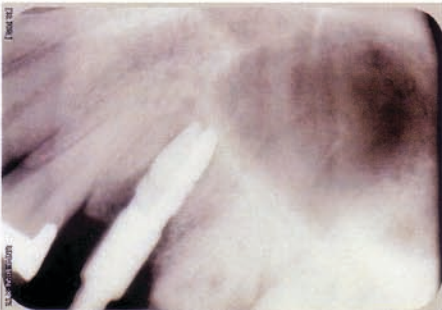3.5mmØ hatch reamer™ at 9mm



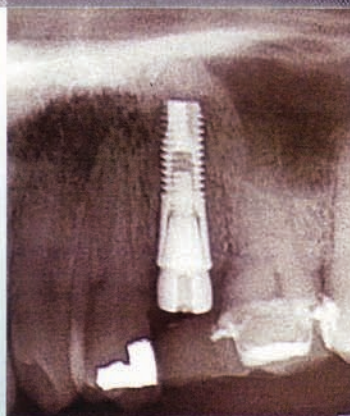
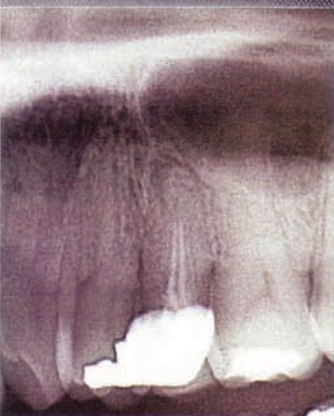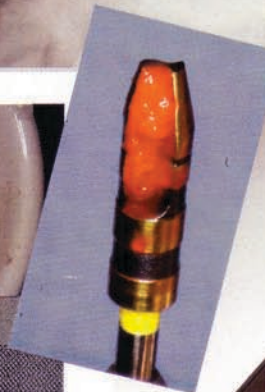4.0mmØ hatch reamer™ at 11mm with bone graft material



4.5mmØ x 13mm Astra implant placed with bone graft material



A composite graft of autogenous bone (collected on hatch reamer blade), mineralized allograft (Mineross™) and calcium sulfate (Tissue Specialists) was used in this case.



*Surgery*

Performed by **Jin Y. Kim, DDS, MPH, MS**

Diplomate, American Board of Periodontology  
 Diplomate, American Board of Oral Implantology/Implant Dentistry  
 Fellow, International Congress of Oral Implantologists  
 Fellow, American Academy of Implant Dentistry  
 Lecturer, UCLA School of Dentistry

MISE™ Case Report #3